

# The role of transvaginal and Doppler ultrasound in differentiating benign from malignant endometrial pathologies in women with postmenopausal bleeding

*El papel de la ecografía transvaginal y Doppler en la diferenciación de patologías endometriales benignas de malignas en mujeres con hemorragia posmenopáusicas*

Zainab Sami Yaseen<sup>1</sup>, <https://orcid.org/0000-0002-9181-7571>, Noor Kathem Nee'ma Al-Waely<sup>2</sup> <https://orcid.org/0000-0002-0723-7727>, Enas Adnan Abdulrasul Khazaali<sup>2</sup> <https://orcid.org/0000-0002-6719-2241>

<sup>1</sup>Dayala Health Director/ MOH/ Iraq.

<sup>2</sup>College of medicine, Al-Nahrain University/Iraq.

\*corresponding author: Enas Adnan Abdulrasul Khazaali, College of medicine, Al-Nahrain University/Iraq. Email: enas.a.alrasol@gmail.com  
Received/Recibido: 05/12/2020 Accepted/Aceptado: 06/15/2020 Published/Publicado: 07/20/2020

206

## Abstract

**Background:** Postmenopausal hemorrhage is usual clinical sign of endometrial cancer occurrence. Transvaginal Doppler ultrasound has emerged as an adjuvant to conventional B-mode imaging in the evaluation of postmenopausal women with potential endometrial carcinoma presenting with bleeding.

**Aim:** the aim of the study is to investigate the role of measurement of the resistive index (RI) of the uterine arteries coupled with transvaginal ultrasound use to differentiate benign and malignant in female with endometrial lesion after menopause associate with hemorrhage.

**Methods:** across sectional study directed on selected 43 female patients older than 50 years complaining from postmenopausal bleeding referred for ultrasound assessment during the period between June 2018 and August 2019. Eligible patients were examined with trans-abdominal ultrasound then transvaginal scanning was complete by calculate the endometrium width. Doppler questioning of the available uterine artery was achieved at the same

session with measurement of the resistive index (RI).

**Results:** the mean age of the patients was (57) years. Out of 43 patients, 25 (58.1%) had simple hyperplasia, 8 patients (18.6%) endometrial carcinoma, 6 patients (13.95%) had polyps and 4 (9.3%) showed non-specific findings. The mean endometrial thickness in cases of adenocarcinoma was (16.6) mm. There was no significant association between endometrial thickness and histopathological diagnosis with a P value 0.054. The mean resistive index of the uterine arteries in endometrial cancer was 0.53. the difference significantly occur in uterine artery RI was found between cases of endometrial carcinoma and other benign endometrial lesions encountered in the study.

**Conclusion:** the mean resistive index of the uterine arteries in cases of endometrial carcinoma is significantly lower than the mean RI in benign endometrial lesion.

**Key words:** postmenopausal bleeding, transvaginal ultrasound, Doppler study.

## Resumen

La hemorragia posmenopáusicas es un signo clínico habitual de aparición de cáncer de endometrio. La ecografía Doppler transvaginal se ha convertido en un adyuvante de la imagenología convencional en modo B en la evaluación de mujeres posmenopáusicas con carcinoma endometrial potencial con hemorragia.

**Objetivo:** el objetivo del estudio es investigar el papel de la medición del índice resistivo (RI) de las arterias uterinas

junto con el uso de ultrasonido transvaginal para diferenciar las lesiones benignas y malignas en mujeres con lesión endometrial después de la menopausia asociada con hemorragia.

**Métodos:** en un estudio transversal dirigido a 43 pacientes femeninas seleccionadas mayores de 50 años que se quejaron de hemorragia posmenopáusicas remitidas para una evaluación de ultrasonido durante el período comprendido entre junio de 2018 y agosto de 2019. Los

pacientes elegibles fueron examinados con ultrasonido transabdominal y luego se completó la exploración transvaginal calculando el ancho de endometrio. El cuestionamiento Doppler de la arteria uterina disponible se logró en la misma sesión con la medición del índice resistivo (IR).

**Resultados:** la edad media de los pacientes fue (57) años. De 43 pacientes, 25 (58.1%) tenían hiperplasia simple, 8 pacientes (18.6%) carcinoma endometrial, 6 pacientes (13.95%) tenían pólipos y 4 (9.3%) mostraron hallazgos inespecíficos. El grosor endometrial medio en casos de adenocarcinoma fue de (16.6) mm. No hubo asociación significativa entre el grosor endometrial y el diagnóstico histopatológico con un valor de  $P = 0.054$ . El índice resistivo medio de las arterias uterinas en el cáncer de endometrio fue de 0,53. La diferencia que ocurre significativamente en la arteria uterina RI se encontró entre los casos de carcinoma endometrial y otras lesiones endometriales benignas encontradas en el estudio.

**Conclusión:** el índice resistivo medio de las arterias uterinas en casos de carcinoma endometrial es significativamente más bajo que el IR medio en la lesión endometrial benigna

**Palabras clave:** sangrado posmenopáusico, ecografía transvaginal, estudio Doppler.

surement of the resistive index (RI) of the uterine arteries coupled with transvaginal ultrasound use to differentiate benign and malignant in female with endometrial lesion after menopause associate with hemorrhage.

### Patients and methods

**Study Design:** A cross sectional analytic study. This study was conducted at the time period between June 2018 and August 2019 at the ultrasound unit \radiology department in Al Immamain AL -Kadhymain medical city. **Inclusion criteria:** In this study, women complaining from postmenopausal bleeding aged  $\geq 50$  years referred for ultrasound assessment were included.

**Exclusion criteria:**

1-Endometrial thickness less than 5mm

2-Women on hormone replacement therapy.

3-Women with cervical pathology.

4-The presence of adnexal mass.

5-Patients in whom histopathological confirmation was not obtained.

6-Un-married women in whom TVS cannot be performed.

**Examination technique:**

Relevant clinical history was retrieved from the eligible patients regarding their age, parity, duration and amount of bleeding and whether or not they have taken any type of hormone replacement therapy. Included patients were examined trans abdominally in the supine position with full bladder utilizing a convex ultrasound probe (3.5 MHz) by a high end ultrasound unit (Voluson E6, GE healthcare). Afterwhich, the patient was asked to empty the bladder and transvaginal scanning was done in the lithotomy position under sterile technique using a high frequency transvaginal probe (7.5 MHz). First, straight grey gauge US checkup of the uterus was done and records were completed concerning its position, orientation and deviation from mid sagittal plane and whether or not this affects the uterine arteries. Transverse and longitudinal section of endometrium was scrutinized (homogeneity of endometrium, hyper-echogenic internal endometrial structure and regularity of endo-myometrial border). Full endometrial width (dual coating) was occupied at sagittal segment. At that time, an exploration for the available uterine artery was prepared. When the artery has been recognized, the beat Doppler example capacity was triggered to get a flow velocity waveform (FVW). The resistive index (RI) was measured. Clinical and ultrasound data were collected and later on compared with final histopathological diagnosis of the endometrium which was obtained from dilation and curettage or after surgical hysterectomy.

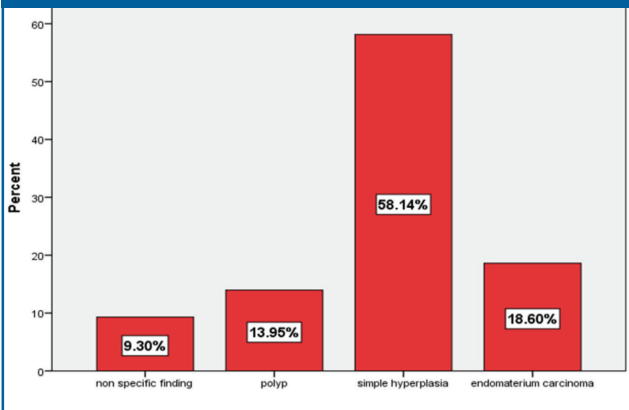
**Statistical analysis:** the statistical analysis done by SPSS v. 23, where frequency and percentage of included patients were calculated, categorical data and significant association between them was evaluated by chi-square, continuous data and significant association between them tested

**P**ostmenopausal hemorrhage is a usual clinical sign of endometrial cancer occurrence<sup>1</sup>. Near to 10 – 15 % of females diagnosis as hemorrhage after menopause are eventually have endometrium ca<sup>2,3</sup>. Endometrium hemorrhage after menopause have multiple causes: hyperplasia, polyp, carcinoma of endometrium, ca. of cervical, leiomyosarcoma of uterine<sup>4</sup>. Numerous altered study apparatuses have been revealed to be beneficial in finding and description of endometrial abrasions in females with irregular uterine hemorrhage. These examination tools are (D&C) dilatation then curettage, U/S transvaginal, hysteroscopy with calculated the endometrium thickness. Measurement of the endometrial thickness is the basic step in the ultrasonographic evaluation of pathological conditions of the uterus. Prior studies showed its efficacy in prediction of endometrial cancer<sup>5</sup>. Assessment of the endometrial morphology, with or without saline infusion (saline contrast sonohysterography (SCSH))<sup>6-8</sup> has also been shown to be valuable in diagnosing endometrial lesions. Color Doppler of the endometrial lining and spectral Doppler ultrasound of the uterine and sub endometrial arteries has been postulated to aid in prediction of malignant endometrial lesions<sup>9,10</sup>. On the other hand, several researchers have documented substantial overlap between benign and malignant endometrial pathologies, limiting the usefulness of Doppler study<sup>11,12</sup>. The aim of the study is to investigate the role of mea-

by (Mann-Whitney) Z test and Kruskal Wallis Test. Correlation of data calculated by Pearson Correlation. P-value was considered significant if  $< 0.05$ .

**D**escriptive study: our study included 43 women with mean age of  $57 \pm 6$  years. Mean endometrial thickness was  $(12.8 \pm 7.2)$  mm. In this study, the histopathological diagnosis were as follows: 58.1% having simple hyperplasia, 18.6% endometrium carcinoma, 13.95 % polyp and 9.3 % non-specific finding (figure 1)

**Figure 1: distribution of women according to histopathological diagnosis**



As shown in table 1, the mean endometrial thickness in cases of endometrial carcinoma is 16.625 mm, in cases of endometrial hyperplasia the mean thickness is 11.96 mm, 15.1 mm for endometrial polyps. No difference between endometrial carcinoma and other benign histopathological diagnoses ( $P\text{-value} > 0.05$ ) in the mean endometrial width.

**Table 1: mean endometrial thickness according to histopathological diagnosis**

Histopathological diagnosis	Number of patients	Mean endometrial thickness	Chi	P-value
Simple hyperplasia	25	11.96		
Endometrial carcinoma	8	16.625		
Polyp	6	15.1	7.65	0.054
Non-specific findings	4	7.25		
Total	43			

Kruskal Wallis Test,  $P\text{-value} > 0.05$  (not significant).

RI mean of the uterine artery in female with ca. of endometrium (0.53). In simple hyperplasia 0.77, in polyps 0.78 as shown in table 2.

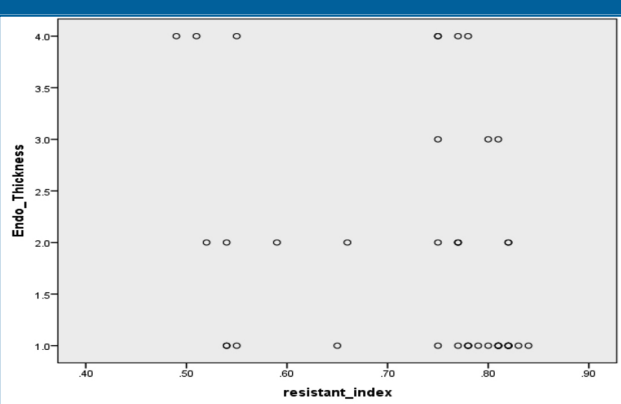
**Table 2: Mean RI of uterine arteries according to histopathological diagnosis**

Histopathological diagnosis	Number of patients	Mean RI	Chi	P-value
Simple hyperplasia	25	0.77		
Endometrial carcinoma	8	0.53		
Polyp	6	0.78	21.83	0.0001
Non-specific findings	4	0.81		
Total	43			

Kruskal Wallis Test,  $P\text{-value} < 0.05$  not significant.

There is negative correlation between endometrial thickness and resistive index, meaning when endometrial thickness increases, the resistive index decreases. With significant Spearman's rho correlation  $0.003^{**}$ . (figure 2)

**Figure 2: correlation between endometrial thickness and resistive index.**



Correlation Coefficient =  $- 0.438^{**}$ ,  $P\text{ value} = 0.003^{**}$  (significant)

Tables 3, 4 and 5 show significant difference  $< 0.05$  in resistive index between endometrial carcinoma and other histopathological diagnoses.

**Tables 3**

	Histopathological diagnosis	N	Mean	SD	Z	P-value
Resistive index	Nonspecific finding	4	0.81	0.03	2.74	0.006
	Endometrium carcinoma	8	0.53	0.02		
	Total	12				
Resistive index	Polyp	6	0.78	0.03		
	Endometrium carcinoma	8	0.53	0.02	3.12	0.002
	Total	14				
Resistive index	Simple hyperplasia	25	0.77	0.06		
	Endometrium carcinoma	8	0.53	0.02	4.23	0.0001
	Total	33				

(Mann-Whitney) Z test,  $P\text{-value} < 0.05$  (significant).

The most common endometrial pathology encountered in this study was simple hyperplasia seen in 58.1% of women. In total, 35 out of 43 patients (81.39%) had benign endometrial pathologies (hyperplasia, polyp and non-specific changes) a finding similar to a study done by AbdelMaboud et al.<sup>13</sup> in which benign endometrial lesions represented the majority of the cases (38 out of 50). Endometrial carcinoma represented 18.6 % of the cases. A findings which is slightly higher than the 10-15% incidence reported in the literature<sup>2,3</sup>. On the other hand, in the study of AbdelMaboud et al.<sup>13</sup> carcinoma represented 26% of the total cases evaluated. A significant association was found between endometrial thickness and the histopathological diagnosis with higher mean endometrial thickness in endometrial carcinoma (16.6 mm) than in other benign pathologies. Karlsson et al study stated a higher mean endometrial width in females with ca. of endometrium was (21.1 mm)<sup>14</sup>, whereas in Botsis et al study the mean endometrial width in females with ca. of endometrium was similar to current study was (16.6 mm)<sup>15</sup>. Several previous researches have incorporated Doppler examination whether color or pulsed in the evaluation of endometrial pathologies in postmenopausal women. In our study, the mean RI of the uterine artery in females of endometrial carcinoma was (0.53). This is in accordance with several previous studies which stated an approximate value of mean RI in cases of endometrial carcinoma. Dragojević et al.<sup>16</sup> showed RI means of uterine arteries in patients had endometrial adenocarcinoma was (0.51). AbdelMaboud et al.<sup>13</sup> stated the mean RI in cases of endometrial cancer was 0.5. Kucur et al<sup>17</sup> reported RI means of the twisting artery was (0.44) in females of endometrial adenocarcinoma. A significant association between RI and endometrial pathologies was shown with negative correlation (P value=0.003) with significantly lower mean RI in endometrial cancer than in other benign endometrial lesions. The available literature has somewhat controversial data regarding the value of using Doppler spectral parameters in the evaluation of endometrial pathologies. The result of our study with regards to Doppler indices is similar to several previous studies which stated that low RI is significantly associated with endometrial cancer in such way that when RI decreases there is increased likelihood of malignancy. In the study of AbdelMaboud et al.<sup>13</sup> the authors concluded that there is statistically significant association between Doppler directories ( PI & RI) spiral arteries and uterine, uterine endometrial pathologies and he stated that the mean RI of uterine arteries in cases of endometrial carcinoma is significantly lower than in other pathologies. Likewise, Kucur et al.<sup>17</sup> found significant correlation between spiral artery Doppler indices and the risk of malignancy in endometrial pathologies. Englert-Golon et al.<sup>18</sup> stated meaningfully lesser RI in the endometrial arteries then

uterine arteries in females with ca. of endometrium after that in females had hyperplasia of endometrial. Bano et al.<sup>19</sup> found that using RI=0.81 as cut off value for discriminating benign and malignant endometrium, sensitivity was 62.5%, specificity 53.33%, PPV – 26.3% and NPV as 84.2%. Develioglu et al.<sup>20</sup> showed RI of uterine artery is self-determining variable that used with ET, so the ET sensitivity raise to reach 97%, and for endomaterum illness or ca. reach to 93%, speceficity decrease to reach 58% & 53% correspondingly. They concluded that evaluation of Doppler indices of uterine arteries had no effect high than ET calculation in assessing PMB. Dragojević et al.<sup>16</sup> showed that decrease Doppler strictures lead to high +ve predictive value at uterine vessels level in assessing any changing of endometrium pathology. So, the conclusion that Doppler evaluation is helpful in the diagnostic work-up of endometrial pathologies and adds to the accuracy of conventional grey-scale ultrasound in discriminating benign from malignant endometrial lesions, it is however not specific enough to obviate the need for pathological diagnosis. Their conclusion agrees with the results of another study by Arslan et al.<sup>21</sup> who stated that Doppler ultrasound may be helpful in patients who do not complain with invasive methods in groups they are at small danger to have ca. of endometrium.(This is not what the cited work states.) They say: “it may be helpful in cases in which invasive techniques are difficult to perform and in the differentiation of a certain group of patients at little risk of endometrial carcinoma.”

## Conclusions

Transvaginal Doppler ultrasound is a noninvasive technique which has a potential important place in the diagnostic diagnosis for the calculation of females with postmenopausal hemorrhage. Transvaginal Doppler evaluation of the uterine arteries can help in prediction of endometrial adenocarcinoma. Resistive index of the uterine arteries is significantly lower in endometrial carcinoma than in other pathologies which cause endometrial thickening in patient with postmenopausal bleeding.

## References

- 1- Aboul-Fotouh, M. E. M., Mosbeh, M. H., El-Gebaly, A. F. & Mohamed, A. N. Transvaginal power Doppler sonography can discriminate between benign and malignant endometrial conditions in women with postmenopausal bleeding. Middle East Fertility Society Journal 17, 22–29 (2012).
- 2- Breijer, M. C., Timmermans, A., van Doorn, H. C., Mol, B. W. J. & Opmeer, B. C. Diagnostic Strategies for Postmenopausal Bleeding. Obstetrics and Gynecology International 2010, 1–5 (2010).
- 3- Alcazar, J. L. & Galvan, R. Three-dimensional power Doppler ultrasound scanning for the prediction of endometrial cancer in wom-



- en with postmenopausal bleeding and thickened endometrium. American Journal of Obstetrics and Gynecology 200, 44.e1-44.e6 (2009).
- 4- Appleton, K. & Plavsic, S. K. Role of ultrasound in the assessment of postmenopausal bleeding. Donald School Journal of Ultrasound in Obstetrics and Gynecology 6, 197–206 (2012).
  - 5- Smith-Bindman R, Kerlikowske K, Feldstein VA, Subak L, Scheidler J, Segal M, Brand R, Grady D. Endovaginal ultrasound to exclude endometrial cancer and other endometrial abnormalities. JAMA 1998; 280: 1510–7 .
  - 6- Epstein E, Ramirez A, Skoog L, Valentin L. Transvaginal sonography, saline contrast sonohysterography and hysteroscopy for the investigation of women with postmenopausal bleeding and endometrium > 5mm. Ultrasound Obstet Gynecol 2001; 18: 157–62
  - 7- Sheth S, Hamper UM, Kurman RJ. Thickened endometrium in the postmenopausal woman: sonographic-pathologic correlation. Radiology 1993; 187: 135–9
  - 8- Hulka CA, Hall DA, McCarthy K, Simeone JF. Endometrial polyps, hyperplasia, and carcinoma in postmenopausal women: differentiation with endovaginal sonography. Radiology 1994; 191: 755–8.
  - 9- Kurjak A, Shalan H, Sosic A, Benic S, Zudenigo D, Kupesic S, Predanic M. Endometrial carcinoma in postmenopausal women: evaluation by transvaginal color Doppler ultrasonography. Am J Obstet Gynecol 1993; 169: 1597–603
  - 10- Bourne TH, Campbell S, Steer CV, Royston P, Whitehead MI, Collins WP. Detection of endometrial cancer by transvaginal ultrasonography with color flow imaging and blood flow analysis: a preliminary report. Gynecol Oncol 1991; 40: 253–9.
  - 11- Sladkevicius P, Valentin L, Marsal K. Endometrial thickness and Doppler velocimetry of the uterine arteries as discriminators of endometrial status in women with postmenopausal bleeding: a comparative study. Am J Obstet Gynecol 1994; 171: 722–8
  - 12- Sheth S, Hamper UM, McCollum ME, Caskey CI, Rosenshein NB, Kurman RJ. Endometrial blood flow analysis in postmenopausal women: can it help differentiate benign from malignant causes of endometrial thickening? Radiology 1995; 195: 661–5
  - 13- Abdelmaboud, N. M. & Elsaid, H. H. Role of transvaginal ultrasonography and colour Doppler in the evaluation of postmenopausal bleeding. Egyptian Journal of Radiology and Nuclear Medicine 46, 235–243 (2015).
  - 14- Karlsson, B., Granberg, S., Wikland, M., Ryd, W. & Norström, A. Endovaginal scanning of the endometrium compared to cytology and histology in women with postmenopausal bleeding. Gynecologic Oncology 50, 173–178 (1993).
  - 15- Botsis, D., Kassanos, D., Pyrgiotis, E. & Zourlas, P. A. Vaginal sonography of the endometrium in postmenopausal women. Clinical and Experimental Obstetrics and Gynecology 19, 189–192 (1992).
  - 16- Dragojević, S., Mitrović, A., Dikić, S. & Canović, F. The role of transvaginal colour Doppler sonography in evaluation of abnormal uterine bleeding. Archives of Gynecology and Obstetrics 271, 332–335 (2005).
  - 17- Kucur, S. K. Contribution of spiral artery blood flow changes assessed by transvaginal color Doppler sonography for predicting endometrial pathologies. Dicle Medical Journal/Dicle Tıp Dergisi 40, 345–349 (2013).
  - 18- Englert-Golon, M., Szpurek, D., Moszyński, R., Pawlak, M. & Sajdak, S. Clinical value of the measurement of blood flow in uterine arteries and endometrial vessels in women with postmenopausal bleeding using “power” angio Doppler technique. Ginekologia polska 77, 759–763 (2006).
  - 19- Bano I. A Study of Endometrial Pathology by Transvaginal Color Doppler Ultrasonography and its Correlation with Histopathology in Postmenopausal Women. 002(April):134–9; 2013
  - 20- Develioglu, O. H., Bilgin, T., Yalcin, O. T. & Özalp, S. Transvaginal ultrasonography and uterine artery Doppler in diagnosing endometrial pathologies and carcinoma in postmenopausal bleeding. Archives of Gynecology and Obstetrics 268, 175–180 (2003).
  - 21- Arslan, M. et al. Transvaginal color Doppler ultrasonography for prediction of pre-cancerous endometrial lesions. International Journal of Gynecology and Obstetrics 80, 299–306 (2003).



[www.revhipertension.com](http://www.revhipertension.com)

[www.revdiabetes.com](http://www.revdiabetes.com)

[www.revsindrome.com](http://www.revsindrome.com)

[www.revistaavft.com](http://www.revistaavft.com)