



Immediate and intermediate term results of cheatham platinum stenting for native coarctation of aorta in adults

 Amjad R. Bairam. Dr. FIBMS (med), CABMS (med) FIBMS cardiology: consultant interventional cardiologist/ Ibn Al Bitar cardiac centre. Iraq. arbairam@yahoo.com.

 Ali H. Ali dr. MBCHB, FIBMS (med), FIBMS cardiology, Baghdad, Iraq. shekhanali@yahoo.com.

 Haider J. Al Ghizzi Ass. Prof. Dr. FICMS (med), FIBMS cardiology. Medical Collage/ Karbala University/Iraq. haiderjibr72@gmail.com.

Received/Recibido: 04/21/2021 Accepted/Aceptado: 05/15/2021 Published/Publicado: 06/10/2021
DOI: <http://doi.org/10.5281/zenodo.5651255>

Abstract

Background: aortic coarctation is an important cause of hypertension. Surgical repair was considered the conventional treatment for native aortic coarctation while stenting emerged recently as an alternative to surgical repair. **Objective:** To evaluate the immediate and intermediate results of Cheatham Platinum (CP) stenting for native coarctation of aorta. **Methods:** This is a prospective study done in Ibn Al-Bitar cardiac Centre, included 32 consecutive adult patients with native coarctation of aorta. Clinical, hemodynamic and procedural data were collected and analyzed for each patient. Covered CP stent was used and mounted on the Balloon-in-Balloon catheter (BIB) in most of the cases. The technique was considered effective if the invasive grade was decrease to <20 mmHg and increased the angiographic diameter $>50\%$. **Results:** A total of 32 patients had the procedure done with a success rate of 93.4%. Peak gradient across the coarctation fell from 60.0 ± 21.960 to 10.0 ± 19.821 mmHg post procedure (P, 0.0001). There was no major complications, with no deaths. Systolic blood pressures fell from 164.6 ± 25.889 mmHg to 138.1 ± 17.006 mmHg immediately after stenting and 134.3 ± 12 mmHg at 6 months. No significant complications were seen during procedure and at 6 months follow up. **Conclusion:** aortic coarctation stent of adults have better fast clinical and angiographic consequences and continued hemodynamic advantages at 6-12 months.

Keywords: Immediate and intermediate, cheatham platinum, native coarctation, aorta.

Resumen

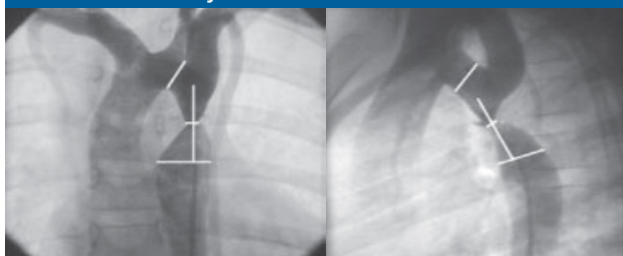Fundamento: la coartación aórtica es una causa importante de hipertensión. La reparación quirúrgica se consideró el tratamiento convencional para la coartación aórtica nativa, mientras que la colocación de stents surgió recientemente como una alternativa a la reparación quirúrgica. **Objetivo:** Evaluar los resultados inmediatos e intermedios de la implantación de un stent Cheatham Platinum (CP) para la coartación nativa de la aorta. **Métodos:** Se trata de un estudio prospectivo realizado en el Centro Cardíaco Ibn Al-Bitar, que incluyó a 32 pacientes adultos consecutivos con coartación de aorta nativa. Se recopilaron y analizaron datos clínicos, hemodinámicos y de procedimiento para cada paciente. En la mayoría de los casos se utilizó un stent CP cubierto y se montó en el catéter con balón (BIB). La técnica se consideró eficaz si el grado invasivo disminuía a <20 mmHg y aumentaba el diámetro angiográfico $>50\%$. **Resultados:** Un total de 32 pacientes se sometieron al procedimiento con una tasa de éxito del 93,4%. El gradiente máximo a través de la coartación se redujo de $60,0 \pm 21,960$ a $10,0 \pm 19,821$ mmHg después del procedimiento (P, 0,0001). No hubo complicaciones mayores, sin muertes. La presión arterial sistólica descendió de $164,6 \pm 25,889$ mmHg a $138,1 \pm 17,006$ mmHg inmediatamente después de la colocación del stent y $134,3 \pm 12$ mmHg a los 6 meses. No se observaron complicaciones significativas durante el procedimiento y a los 6 meses de seguimiento. **Conclusión:** el stent de coartación aórtica en adultos tiene mejores consecuencias clínicas y angiográficas rápidas y ventajas hemodinámicas continuas a los 6-12 meses.

Palabras clave: Inmediato e intermedio, cheatham platinum, coarctación nativa, aorta.

Coarctation of the aorta (COA) is well-defined as a separate stenosis of the proximal thoracic aorta frequently at the insertion point of the ductus arteriosus, it accounts for about 6-8% of patients with congenital heart disease with a male/female ratio in a range from 1.4:1 to 3:1^{1,2}. Eighty five percent of patient with COA have an associated bicuspid aortic valve. The most important extra cardiac vascular abnormalities associated with COA are the Berry aneurysm, variation in the brachiocephalic artery anatomy and the collateral arterial circulation¹. Magnetic Resonance Imaging (MRI) and Multidetector CT angiography can provide excellent anatomic diagnosis in patients with coarctation and aortic arch anomalies³. In adolescent & adults the coarctation of the aorta should be repaired in patients with >20 mm Hg peak-to-peak gradient, or in patients with < 20 mm Hg gradient with significant angiographic/imaging evidence of a narrowing⁴. Surgical repair of coarctation bears several potential Problems including a significant incidence of aneurysm formation, recoarctation, aortic dissection and Paraplegia, Operating mortality is unusual⁵⁻⁷. Balloon angioplasty suggested as the favored management for adults and children they have coarctation or recoarctation afterward operation. The main problem of angioplasty only is shrinking of wall of vessel with stenosis reappearance, separation of aortic wall occur in 1-4% of total patients, and creation of aneurysm in 4-11%. Next balloon enlargement, about 21-37% continue hypertensive⁸⁻¹⁰. Stents supposedly by metal support may decrease the occurrence of serious elastic recoil as well as late restenosis. Decreases or cessation of anti-hypertensive treatment next to stent inserting attained in 41-88% of the patients¹¹. Enclosed stents specially in patients there is remnants wall of aortic aneurysm, close-fitting native coarctation is found and dilation of balloon stent associate with danger of dissection, also related to arterial ducts where the vessels of old age patients are little resistant. Left subclavian artery well tolerate to obstruction, intact of vertebrobasilar system must diagnose before operation. The covered stents are balloon expandable or self-expanding. In cases of a much-fitted coarctation of the aorta, a theatrical methodology may be a harmless optimal^{11,12}. The aim of study is to assess the direct and intermediate consequences of Cheatham Platinum (CP) stenting for native coarctation of aorta.

This is a prospective study performed in Ibn-AL-Bitar cardiac center, for the period from Feb-2011 to Feb-2015, Included 32 consecutive adult patients with native coarctation who underwent aortic stent placement with CP stents implantation (NuMed CP stent, Heart Medical Europe BV, Best, the Netherlands). Patients included in this study were those who were referred with clinical evidence for COA (hypertension, arm-leg blood pressure (BP) difference ≥ 20 mmHg), for whom the diagnosis of COA was confirmed by both transthoracic echocardiography and by CT angiography. Finally confirmed during the interventional procedure. Standard angiographic projections (angled 15° LAO and 10° caudal), followed by measurement of the gradient across the COA. Measurements are then made of the distal transverse arch diameter, coarctation diameter, coarctation length, distal normal vessel diameter, and distance from the left subclavian artery origin to the coarctation, and diameter of the left subclavian artery. Fig 1

Figure.1 Lateral and antero-posterior angiogram of native coarctation with key measurements shown



After measurements had been taken the appropriate size stents and delivery balloons were chosen. The initial balloon size was selected on the basis of the smallest diameter proximal to the coarctation segment; Covered CP stent was hand crimped on a balloon dilation catheter (either Z-med balloon dilatation catheter or BIB balloon according to availability in the stock) and advanced within the sheath (12-14 F) to the coarctation site over the amplatz super stiff wire anchored in the right or left subclavian artery according to the angle of the coarctation. The stent then inflated (hand inflated 50 cc syringe) after securing its position with contrast injection with or without the assistance of rapid ventricular pacing. The technique was considered effective if the invasive grade was decrease to <20 mmHg and increased the angiographic diameter >50%. After the procedure, the patient discharged on aspirin 300 mg daily for six months, and given antihypertensive drug treatment when necessary. Repeated echocardiographic examinations performed 24 hours after the procedure to evaluate stent localization and the presence of residual gradients. Follow up ranged from 6-32 months (mean 14.9 Months) included clinical, echocardiographic and CT exam assessing for restenosis, aneurysm formation, stent migration, blood pressure control and the intensity of antihypertensive medications.

A total of 32 native coarctation patients were involved in this study 15 patients were male (46.9%) and 17(53.1%) patients were female, with their age range from 16–58 years (mean 30.83 ± 11.179), with bicuspid aortic valve disease with stenosis or regurgitation as the most common associated cardiac anomaly as in table 1

TABLE 1. Patient Characteristics

Age distribution (yr.)	
Minimum	16
Maximum	56
Mean \pm SD	30.83 ± 11.179
Sex distribution	
Male	15 (46.9%)
Female	17 (53.1%)
Associated cardiac abnormalities	
BAV	16 (50.0%)
AS	5 (15.6%)
AR	11 (34.4%)
VSD	2 (6.7 %)
PDA	1 (3.3%)
MVP	4 (13.3%)

AR=aortic regurgitation; AS= aortic stenosis; BAV=bicuspid aortic valve; MVP= mitral valve prolapse; PDA= patent ductus arteriosus VSD= ventricular septal defect. The overall success rate was 93.4 % (31 patient), with 39 stents implanted, The CP stent used in 30 patients, and uncovered stent was used only in one patient to avoid the occlusion of the left subclavian artery. The mean stent length was (29.6 ± 9) mm. the immediate angiographic and hemodynamic results summarized in table 2. At hospital discharge, 19 patients still had hypertension. 13 of 32 patients (40.6%) without anti-hypertensive treatment at the period of discharge. In 14 (43.7%), anti-hypertensive treatment was reduced and in another 5 patients (18.7%) the same anti-hypertensive treatment was continued.

TABLE 2. BP and Angiographic Measurements and Gradients across Coarctation

Variable	Mean	SD	P value
PG before and after stenting			
PG before stenting	60.00mmHg	21.960	0.0001
PG after stenting	10.09mmHg	19.821	
AO Diameter before and after stenting			
AO Diameter before stent	5.422 mm	3.1550	<0.001
AO Diameter after stent	16.656 mm	2.5223	
BP changes before and after stenting			
Systolic BP before	164.66 mmHg	25.889	0.0001
Systolic BP after	138.19 mmHg	17.006	
Diastolic BP before	87.00 mmHg	10.892	
Diastolic BP after	85.88 mmHg	15.165	

AO=aorta; BP=blood pressure; PG=pressure gradient; SD=standard deviation

There was no recorded complication at the implantation site except for one case of ruptured balloon used to deliver a second CP stent, the balloon retrieved to the iliac artery then successfully removed surgically. There was no procedure related mortality. For all patients a minimum of 6 months follow up could be achieved, and for 18 (60%) patients follow up could be extended to more than one year. There was no recorded restenosis, aneurysm formation, or stent migration one case of multiple stent implanted had planned for staged dilatation after 6 months unfortunately discontinued aspirin prematurely and lost from follow up until the 18th month following the procedure in whom Angiography showed a much-occluded stent and the patient was referred for surgical repair. Mean systolic blood pressure before treatment was 164.6 mmHg, at six months of follow-up; mean blood pressure (systolic) was 134.3 mm Hg. During follow-up, no any signs of aneurysm creation, dissection diagnosis in any patient.

Discussion

Transcatheter management of CoA in adults with stenting, lead to continue angiographic and hemodynamic advantage directly and at 6-12 months with important decreases in grade and systolic blood pressure. This advantage understood in patients with native coarctation. No any death associated to the CoA during the transcatheter technique or throughout the follow up time. Comparable results were achieved by Patil et al (multicenter study with a success rate ranged 78-91%¹³ and Hamadan et al study reported an excellent initial result in 32 of 33 stented patient with aortic coarctation¹⁴ This study reports relatively lower rate of normalization of blood pressure compared with Lam et al¹⁵ (40.6% vs 79%) (This difference probably related to a lower mean age at time of intervention of this study). Vohra et al reported 46% rate of normalization of hypertension after repair in adult¹⁶. This study did not report periprocedural complication except for one case of ruptured balloon, with almost null periprocedural mortality; reflecting the relative safety of the procedure however many other studies reported various periprocedural complication including balloon rupture, stent migration, acute dissection, and aortic rupture, BIB balloon is an good instrument to prevent stent migration and rupture of balloon during the technique. The chief goals with any management for CoA is continued hemodynamic advantage as supported by control of hypertension. CoA repair by operation results in significant decrease in systolic blood pressure¹⁶. Such outcomes stated in patients >50 years of age undergoing operating repair^{17,18}.

Treating native coarctation of the aorta with stent implantation is a less invasive, safe and highly successful technique with excellent angiographic and clinical response that is sustained to the midterm follow up of this study.

References

1. Washington RL. 50 Years ago in the Journal of Pediatrics: congenital heart disease in the neonatal period. *J Pediatr*. 2014 Nov;165(5):920.
2. Loffredo CA, Chokkalingam A, Sill AM, et al. Prevalence of congenital cardiovascular malformations among relatives of infants with hypoplastic left heart, coarctation of the aorta, and d-transposition of the great arteries. *Am J Med Genet A* 2004; 124:225-230.
3. Nielsen JC, Powell AJ, Gauvreau K, et al. Magnetic resonance imaging predictors of coarctation severity. *Circulation* 2005; 111:622-28.
4. Warnes CA, Williams RG, Bashore TM, et al. ACC/AHA 2008 Am guidelines for the management of adults with congenital heart disease. *J Coll Cardiol*. 2008; 52:143-263.
5. Gatzoulis, M. A., Swan, L., Therrien, J. & Pantely, G. A. Adult Congenital Heart Disease: A Practical Guide. *Adult Congenital Heart Disease: A Practical Guide* (Blackwell Publishing Ltd, 2007), 1–274.
6. Brown ML, Burkhart HM, Connolly HM, Dearani JA, Cetta F, Li Z, Oliver WC, Warnes CA, Schaff HV. Coarctation of the aorta: lifelong surveillance is mandatory following surgical repair. *J Am Coll Cardiol*. 2013 Sep 10;62(11):1020-5.
7. Anagnostopoulos-Tzifa A, Management of Aortic Coarctation in Adults: Endovascular versus Surgical Therapy. *Hellenic J Cardiol* 2007, 48: 290-295.
8. He L, Wu L, Liu F, Qi C, Lu Y, Zhang D, Huang G. [Balloon angioplasty for native coarctation in children: one year follow-up results]. *Zhonghua Er Ke Za Zhi*. 2014 Jul;52(7):535-9.
9. Nance JW, Ringel RE, Fishman EK. Coarctation of the aorta in adolescents and adults: A review of clinical features and CT imaging. *Journal of Cardiovascular Computed Tomography*. 2016 Jan-Feb;10(1):1-12.
10. Walhout RJ, Suttorp MJ, Mackaij GJ, Ernst JM, Plokker HW. Long-term outcome after balloon angioplasty of coarctation of the aorta in adolescents and adults: Is aneurysm formation an issue? *Catheter Cardiovasc Interv*. 2009 Mar 1;73(4):549-56.
11. Horvath R, Towgood A, Sandhu SK. Role of Transcatheter Therapy in the Treatment of Coarctation of the Aorta. *J Invasive Cardiol* 2008; 20(12):660-663.
12. Peters B, Ewert P, Berger F. The role of stents in the treatment of congenital heart disease: Current status and future perspectives. *Ann Pediatr Cardiol*. 2009; 2(1): 3–23.
13. Patil, N. P., Mohite, P. N., Reed, A., Popov, A. F. & Simon, A. R. Modified technique using novalung as bridge to transplant in pulmonary hypertension. *Annals of Thoracic Surgery*. 2015, 99, 719–721.
14. Krasemann T, Bano M, Rosenthal E, Qureshi SA. Results of stent implantation for native and recurrent coarctation of the aorta-follow-up of up to 13 years. *Catheter Cardiovasc Interv*. 2011 Sep 1;78(3):405-12.
15. Lam YY, Kaya MG, Li W, Mahadevan VS, Khan AA, Henein MY, Mullen M. Effect of endovascular stenting of aortic coarctation on biventricular function in adults. *Heart*. 2007 Nov;93(11):1441-7.
16. Vohra HA, Adamson L, Haw MP. Does surgical correction of coarctation of the aorta in adults reduce established hypertension? *Interact Cardiovasc Thorac Surg*. 2009 Jan;8(1):123-7.
17. Vergales JE, Gangemi JJ, Rhueban KS, Lim DS. Coarctation of the aorta - the current state of surgical and transcatheter therapies. *Curr Cardiol Rev*. 2013 Aug;9(3):211-9.
18. Park JH, Chun KJ, Song SG, et al. Severe aortic coarctation in a 75-year-old woman: total simultaneous repair of aortic coarctation and severe aortic stenosis. *Korean Circ J*. 2012;42(1):62-64.